



PATIENT

Ariel Costa

PRESENTING CLINICAL SIGNS

History: Recheck echo. Assess prior to anesthesia.
-Pertinent previous echo findings (3/2022 MML): mild MR, mild LAE, no LVE; LA 1.9, LV 3.1

SPECIES

Canine

ECHOCARDIOGRAM FINDINGS

2D, m-mode, color flow and doppler imaging is available. Diffuse thickening of mitral valve leaflets with mild prolapse into the left atrial lumen. Mild eccentric mitral regurgitation with mild left atrial dilation. Normal MR velocity. Normal LV diameter with adequate myocardial function. The tricuspid valve appears normal with no tricuspid regurgitation. Normal right atrial and ventricular diameter and morphology indicating no overt evidence of pulmonary arterial hypertension. The pulmonic and aortic valves are normal in morphology and mobility. Normal pulmonic and aortic outflow velocities with laminar flow. No obvious aortic or pulmonic insufficiency. No pericardial or pleural effusion noted. No obvious cardiac masses.

BREED

Shih TzuMix

SEX

Female Spayed

CARDIAC CHART

AGE

9 years

CANINE CARDIAC PARAMETERS	MR VMAX (m/s)	TR VMAX (m/s)	LA/AO (Boon method)	LA/AO (Heart Base; Swe)	FS (%)	EF (%)	EPSS (cm)
NORMAL PARAMETER	4.5-5.5	<2.7	1.3	<1.6	28-40	40-100	<0.6
PATIENT	5.4		NM	1.4	50	83	NM
CANINE CARDIAC PARAMETERS	HR (BPM)	AV VMAX (m/s)	PV MAX (m/s)	BODY WEIGHT (kg)	LA 2D short axis Base view (cm)	LVIDd Avg; 2D and m-mode short axis (cm)	LVIDs Avg; 2D and m-mode short axis (cm)
NORMAL PARAMETER	50-100	0.7-1.7	0.7-1.6	BELOW	BELOW	BELOW	BELOW
PATIENT	127	1.2	0.8	8.1	2.0	3.3	1.6
*Normal chamber parameters expressed as a mean value (SD)				3	1.27 (5.3)	2.46 (2.46)	1.36 (5.5)
BODY WEIGHT DEPENDENT PARAMETERS				5	1.40 (4.5)	2.74 (5.2)	1.60 (4.7)
<i>*Note: All measurements based upon multi-modal images and methods. An average value is reported.</i>				10	1.50 (3.8)	3.27 (3.5)	2.06 (3.1)
				15	1.83 (2.0)	3.71 (2.4)	2.43 (2.1)
				20	2.02 (1.9)	4.14 (2.2)	2.80 (2.0)
				25	2.18 (2.4)	4.48 (2.9)	3.10 (2.5)
				30	2.33 (3.3)	4.83 (3.9)	3.39 (3.4)
				35	2.48 (4.3)	5.17 (5.0)	3.69 (4.5)
				40	2.62 (5.2)	5.48 (6.1)	3.96 (5.4)
				50	2.88 (7.1)	6.07 (8.3)	4.46 (7.4)

WEIGHT

17.9lbs

INTERPRETED BY

Maggie Machen Lamy, DVM, DACVIM (Cardiology)

IMAGING PERFORMED BY

C. Belan, DVM

HOSPITAL NAME

Aspen Animal Clinic

REFERRING VET

Dr. Ross

INTERPRETATION OF THE FINDINGS & FURTHER RECOMMENDATIONS

Chronic degenerative valve disease persists without evidence of progression. Mild mitral regurgitation is unchanged, without progressive left heart enlargement. Lack of significant left atrial enlargement indicates the current risk for complication is low. No concurrent issues such as systolic dysfunction or pulmonary hypertension are noted in this study.

INVOICE

28756

Given these findings, no cardiac medications are clearly indicated. Assessment of progression in the future will help predict long term prognosis, which is highly variable at this stage (B1). Omega fatty acid supplementation and mild salt restriction may be of some long-term benefit. Monitor for development of a cough, labored breathing, exercise intolerance or collapse episodes.

DATE

2/2/23



PATIENT

Ariel Costa

SPECIES

Canine

BREED

Shih TzuMix

SEX

Female Spayed

AGE

9 years

WEIGHT

17.9lbs

INTERPRETED BY

Maggie Machen Lamy,
DVM, DACVIM
(Cardiology)

IMAGING PERFORMED BY

C. Belan, DVM

HOSPITAL NAME

Aspen Animal Clinic

REFERRING VET

Dr. Ross

INVOICE

28756

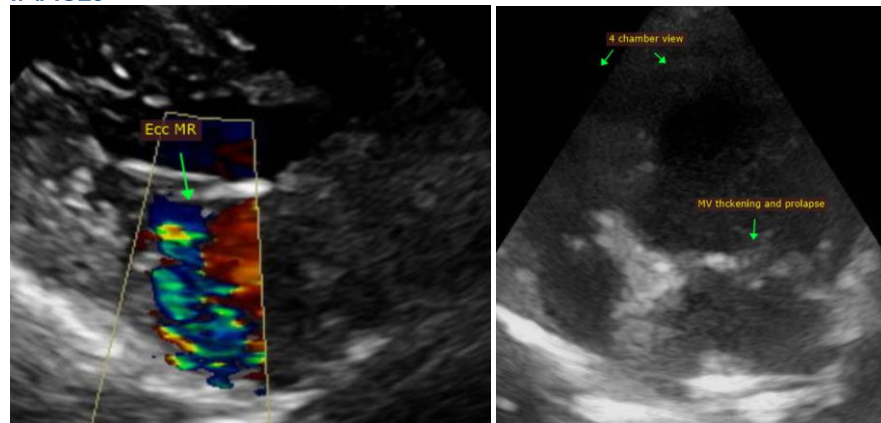
DATE

2/2/23

Anesthetic risk is considered mild if needed. Cardiac protective drug choices (opioid/benzodiazepine premedication, propofol or alfaxalone induction, isoflurane gas) are recommended. Pre-oxygenate for 5-10 minutes prior to induction. Monitor for arrhythmias, hypotension, and hypoxia both intra and post-operatively and intervene as necessary. Mild IV fluid restriction is recommended to avoid fluid overload. Avoid heart rate stimulating drugs such as atropine unless clinically indicated.

Recommend conservative monitoring with a recheck echocardiogram in 6-9 months, sooner if any development of clinical signs.

IMAGES



The information and recommendations provided are based on the images presented by the referring veterinarian. No evaluation can be communicated regarding pathology that was not visible in the image/video clips provided.

Thank you for this referral. This report was generated using transcription software, and minor dictation errors may be present. If the clinical or image interpretation does not parallel your findings or if I can be of any further assistance, please contact me.

Maggie Machen Lamy, DVM
Diplomate of the American College of Veterinary Internal Medicine (Cardiology)
info@sonopath.com